

*pantomographical radiograms, osteosynthesis,  
computer-aided measurement  
of bones dislocation*

Magdalena JEĐRUSIK-PAWŁOWSKA<sup>\*</sup>, Jan DRUGACZ<sup>\*</sup>,  
Aleksander LAMŻA<sup>\*\*</sup>, Zygmunt WRÓBEL<sup>\*\*</sup>

## **ASSESSMENT OF THE RESULTS OF MANDIBULAR FRACTURES SURGICAL TITANIUM MINIPLATES TREATMENT ON THE BASIS OF COMPUTER-AIDED ANALYSIS OF PANTOMOGRAPHICAL RADIOGRAMS**

At present, in mandibular fractures surgical treatment reposition and titanium miniplates osteosynthesis is the most common method used. The treatment results are assessed on the basis of comparative analysis of two radiograms taken before and after fixations of fractures. In this article the objective method of radiological assessment of osteosynthesis is presented. The crucial part of the method is the computer program which was created at The Institute of Computer Biomedical Systems, Silesian University in Katowice. Comparison of placement of bone fragments on a pair of pantomograms taken before and after a particular surgical operation was done. To make the process of the results evaluation an objective one a new parameter – the relative dislocation coefficient – was implemented. Achieved results enable to assess correctness of bone fracture reposition on the pantomographical pictures taken twice, once before and the next time after osteosynthesis.

### 1. INTRODUCTION

A mandible, which creates the lower part of face, is the lowest situated bone of the bony face skeleton. Its built -dense spongy matter situated centrally surrounded by lamina dura- is especially adapted to mechanical works. It is characterized by high tensile and bending strength. The anatomical position of it i.e. being protruded and not protected by any other bones makes it the most liable to suffer an injury part of the bony face, therefore the highest number of skull bones fractures falls to the mandible [9,3].

Muscles, which in the number of 32 are attached symmetrically to the both sides of the mandible, influence substantially on the kind of fractures and accompanying complications [9]. As a result of a bone fracture it comes to disturbances of the muscles balance. Fragments of bones are the subjects of dislocation according to reaction directions of groups of muscles, which are attached to them. The direction of fragments' dislocation after the mandible fracture depends on the place of the fracture, the fracture line course and one of the groups of muscles, which react in a particular direction, domination [1, 9].

---

\* Department of Maxillofacial Surgery Silesian Medical Academy in Katowice; 40-952 Katowice, Francuska 20/24

\*\* Computer Science Department, University of Silesia, 41 – 200 Sosnowiec ul. Będzińska 39

Mandible fractures diagnoses are made on the basis of clinical and radiological symptoms. Radiological examination is compulsory in each case or suspicion of fracture. X-ray pictures should be taken at least in two different exposes. This procedure enables to evaluate properly the fractures and dislocation of fragments [1, 10,12, 19]. Pantomographical radiograms, which are also used to assess treatment results, are sufficient in the majority of cases [1,11,13,15].

When it comes to making plans for treating patients with fractured mandible, both possibilities of orthopedic conservative treatment and recommendations to surgical operations should be taken into account [3,7,8,11]. One of the foremost conditions of fast fracture healing is setting and bringing closer the fragments and the rigid fixation. It is a difficult task because physiological functions of the mandible such as food consuming, swallowing and speaking are associated with movement of it. [1] Making a choice between ways of treatment must take into account the patient's health, so it means that there are no strict rules and every patient should be treated individually [10].

Nowadays the principle is obligatory that surgical setting and osteosynthesis with miniplates bolted to the bones should be carried out as soon as possible [2, 4]. Stable miniplate osteosynthesis eliminates upper jaw-mandibular binding and thanks to that functions of temporo-mandibular joint is preserved, moreover, patients are provided with better food consuming and oral cavity hygiene conditions [1,5,6,9,10,13,15,16]. Plates used differ in size, shape, thickness, elasticity and the number of meshes [2,5,6,13]. Miniplates made of titanium nowadays appear to be the best accepted by patients' organisms ones [2,3,13,18].

## 2. THE AIM

The aim of the article is an attempt to achieve objective radiological assessment of correctness of surgical osteosynthesis of mandibular fractures on the basic of fragments shift in the fracture fissure.

## 3. MATERIAL AND METHOD

The material consists of clinical and radiological of patients records with isolated mandibular fractures treated with miniplate osteosynthesis at the Department and Clinic of Maxillofacial Surgery in Katowice in 1998-2001.

35 patients who were qualified for treatment possessed comprehensive radiological records consisting of a pair of pantomographical radiograms, the first of them had been taken before surgical treatment; the second control one after osteosynthesis.

To standardize the conditions of exposes all the pictures were taken by the same operator and the same Siemens Orthophos ortopantomographical camera, the same kind of film and camera settings were used.

To eliminate fixation errors of patients' heads during examinations which were carried out after some time a simple method was used. The method consists on the control of head positioning by using light beams generated by the camera.

During the first X-ray positions of light beams in the sagittal and orbital planes were marked on the patient's skin in order to obtain exactly the same parameters during the control expose (Fig. 1a, 1b).

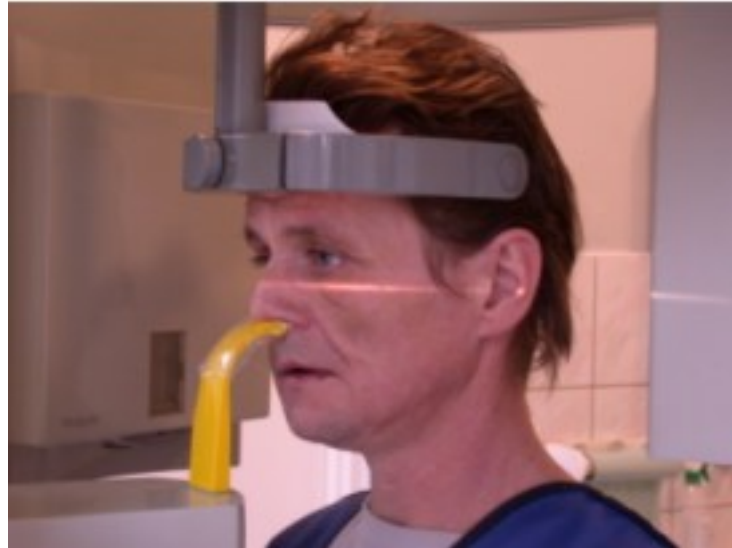

Fig. 1a. Positions of Siemens Orthophos camera light beams on the patient's face before the first X-ray expose

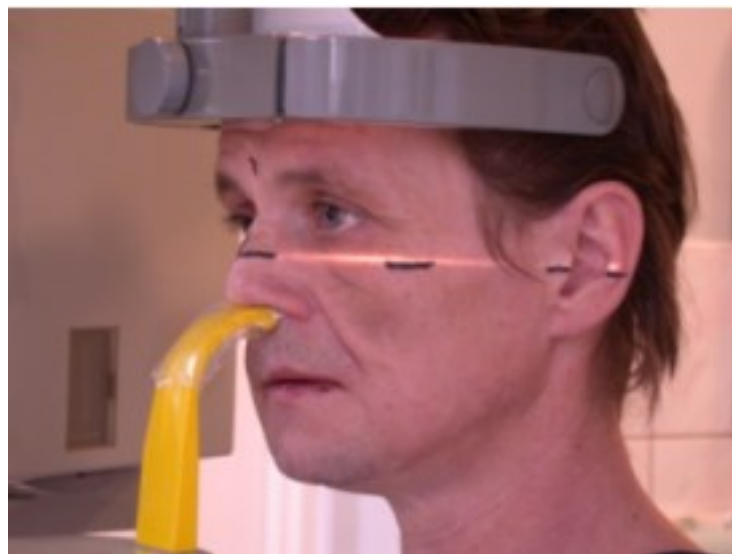

Fig. 1b. Positions of light beams mapped using indelible marker on patient's face

70 pantomographs were subject to the analysis -35 before and the same number after osteosynthesis. The correctness of osteosynthesis of the total number of 49 fractal fissures was analyzed.

The analyses were undertaken using computer system -transparent scanner, computer hardware and software- created at Institute of Computer Biomedical Systems, Silesian University in Katowice. The program consists of two parts. The one part is destined to diminish differences appearing as a result of image defects on the both pantomographs. In order to obtain the above aim

on the both pantomographs three reference points are marked on the upper jaw which considered to be invariable. Thanks to that the pair of radiograms calibration and carrying out further measurements become possible.

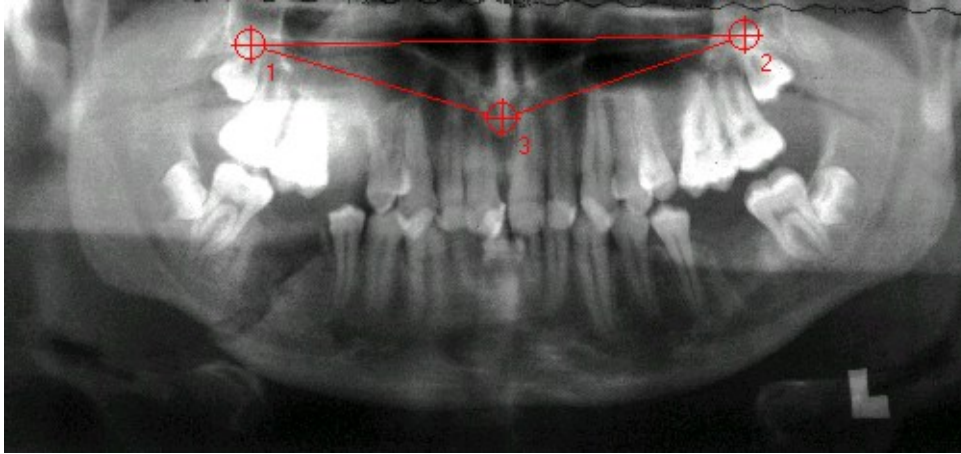


Fig.2. Exemplifying graphical placement of the reference points situated on the upper jaw, enabling to calibrate the pair of pantomographs of M J. patient

The other part of the program is used to analyze fracture fissures. After having chosen two points on the fissure margin before (Fig. 3a) and after osteosynthesis (Fig. 3b) the distance between them is measured and on this basis the relative dislocation coefficient  $dl$  is evaluated.

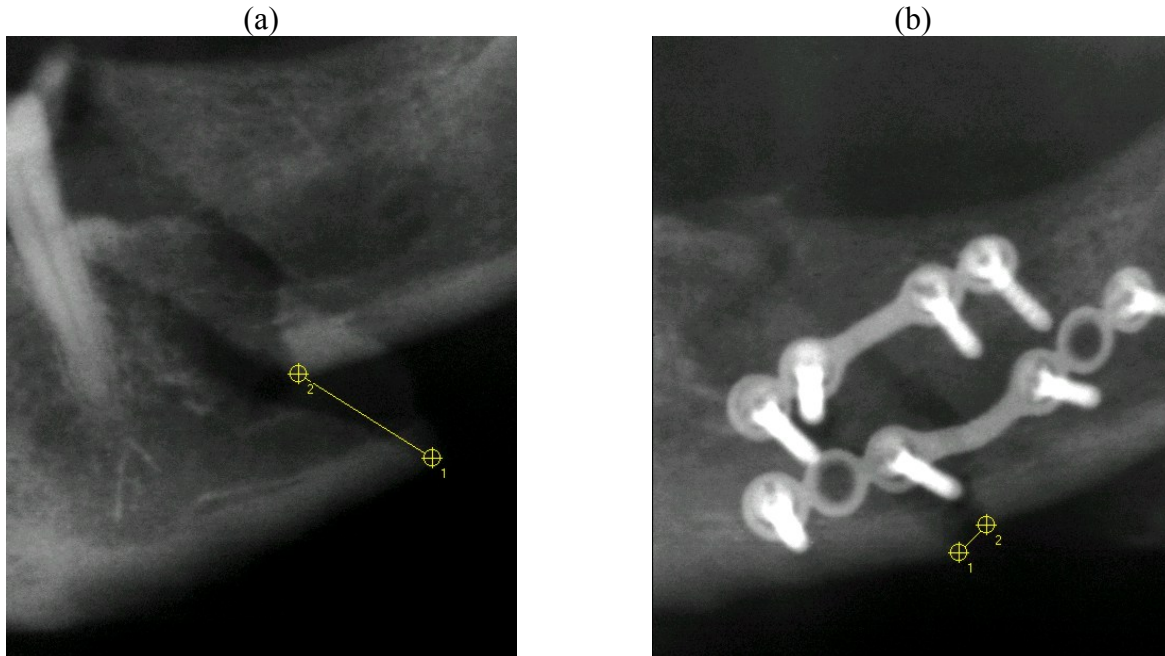


Fig.3a, 3b. Marking reference points 1-2 on the fracture fissure margin before osteosynthesis –picture a- and their shift after osteosynthesis – picture b

Values of  $dl$  coefficient are situated in the range from  $-1.00$  to  $+1.00$ . Negative values of  $dl$  coefficient mean that the fragments after the setting are situated in the unfavorable way. Positive

values of *dl* coefficient signalize that the reposition has been done correctly and bone fragments are located in the way close to anatomical one so osteosynthesis has brought expected results. The *dl* coefficient equals value 0 if there is no difference in the position of the bone fragments before and after osteosynthesis.

#### 4. THE RESULTS AND RECAPITULATION

Up till now, assessment of mandibular fractures treatment results made on the basis of pantomographical radiograms has been done in a subjective way and to great extend seems to be dependant to surgeon's experience. Trying to make this process an objective one, the authors decided to find a computer-aided way of analysis.

Having evaluated searched material the following variation of relative dislocation coefficient *dl* was achieved.

No.	distance between points before osteosynthesis	distance between points after osteosynthesis	dislocation coefficient <i>dl</i>	No.	distance between points before osteosynthesis	distance between points after osteosynthesis	dislocation coefficient <i>dl</i>
1	101,24	81,61	0,11	26	11,05	36,04	-0,53
2	153,21	74,81	0,15	27	63,35	3,58	0,89
3	71,55	49,16	0,19	28	108,19	41,14	0,45
4	25,61	58,03	-0,39	29	22,80	78,98	-0,55
5	195,49	47,61	0,61	30	76,24	56,06	0,15
6	284,12	127,72	0,38	31	41,01	117,32	-0,48
7	47,54	58,23	-0,10	32	76,84	37,31	0,35
8	20,57	15,79	0,13	33	72,24	28,78	0,43
9	65,15	55,13	0,08	34	81,06	34,02	0,41
10	55,03	21,22	0,44	35	31,38	27,13	0,07
11	19,10	24,97	-0,13	36	28,02	22,18	0,12
12	20,40	13,74	0,20	37	26,17	15,93	0,24
13	15,23	42,12	-0,47	38	54,57	17,95	0,50
14	23,35	37,90	-0,24	39	83,57	5,59	0,87
15	37,01	16,63	0,38	40	30,41	37,26	-0,10
16	61,03	38,50	0,23	41	40,05	32,07	0,11
17	49,65	44,79	0,05	42	99,85	27,02	0,57
18	100,50	85,82	0,08	43	36,88	22,81	0,24
19	105,80	31,50	0,54	44	649,15	675,45	-0,02
20	102,65	66,77	0,21	45	52,47	51,30	0,01
21	48,85	33,67	0,18	46	143,41	132,82	0,04
22	17,49	51,40	-0,49	47	167,57	195,63	-0,08
23	79,83	20,75	0,59	48	12,81	11,31	0,06
24	36,50	15,17	0,41	49	28,46	1,93	0,87
25	107,62	32,35	0,54				

Tab.1. Table of measured distances of points on fracture fissure margins and corresponding values of coefficient *dl*

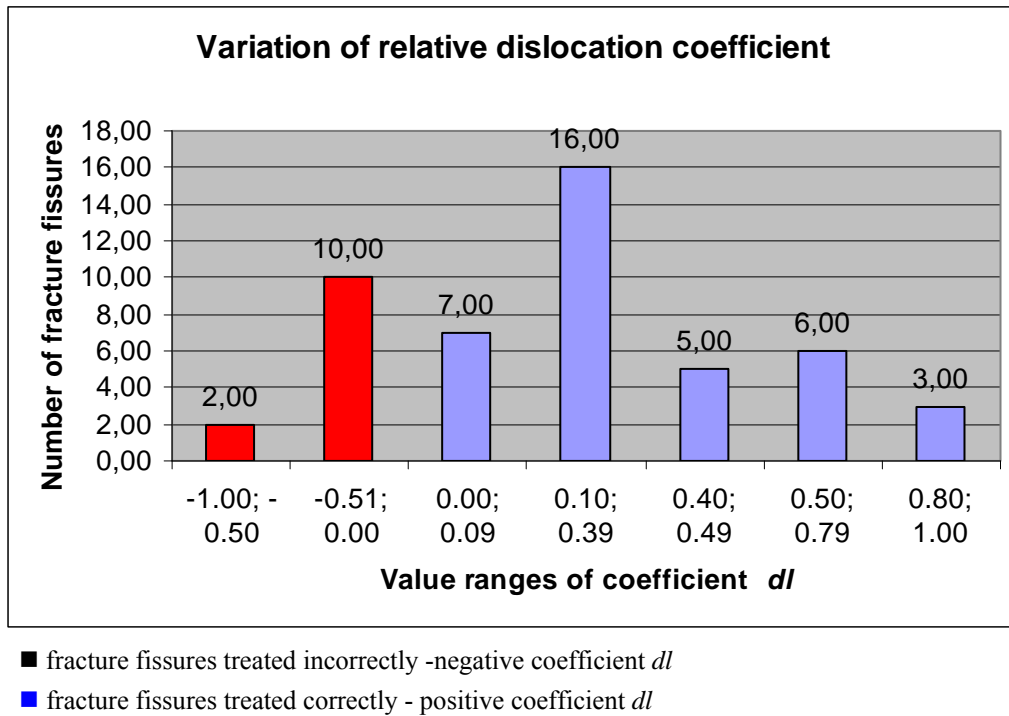


Fig.4. Variation of relative dislocation coefficient

After evaluating the above data, it appeared that in 12 cases -24.4%- relative dislocation coefficient *dl* achieved negative values. It means that in those cases repositions were incorrect – the distance between fragments increased after reposition. In the other 32 cases -75.5%- the coefficient *dl* was positive. Those repositions may be perceived as being successful because fracture fissures were diminished after osteosynthesis.

In the greatest number of cases value of coefficient *dl* is included in the middle range (0.1; 0.39). Value 1 of the coefficient was not obtained even once.

## 5. CONCLUSIONS

1. Implementation of the relative dislocation coefficient *dl* enables measurable assessment of setting correctness on the basis of a pair of analyzed pantomographical radiograms.
2. When two pantomographs of the same patient – before and after osteosynthesis - are compared, image defects become visible what influences on correctness of evaluation of reposition quality. The created computer program should to the high degree minimize the influence of mentioned above distortions on analysis results.

BIBLIOGRAPHY

- [1] BARTKOWSKI S.S. Chirurgia szczękowo-twarzowa. Collegium Medicum UJ, Kraków, 1996.
- [2] CHAMPY M. Microplates in maxillofaciale surgery. Rev. Plast. Surg., 1992, 62, 321-323.
- [3] DEGWI A., MATHOG R. H. Mandible fractures-medical and economic considerations. Otolaryngol. Head Neck Surg., 1993, 108, 3, 213-219.
- [4] ELLISE E. Rigid skeletal fixations of fractures. J. Oral Maxillofac. Surg., 1993, 51, 163-173.
- [5] KNAPIK S., POGORZELSKA-STRONCZAK B. Osteosynteza stabilna i kompresyjna płytkami osteo w leczeniu złamań zuchwy. Chir. Narz.bRuchu Ortop., 1979, 64, 1, 25-28.
- [6] KNAPIK S., STEFAŃSKI W., WĄSEK A., POGORZELSKA-STRONCZAK B., JAWORSKA A., JUZEK W. Osteosynteza stabilna z uwzględnieniem metod własnych w leczeniu złamań twarzoczaszki. Czas. Stomat., 1980, 33, 2, 147-153.
- [7] KREUTZIGER K. L. Comprehensive surgical management of mandibular fractures. South. Med. J., 1992, 85, 5, 506-518.
- [8] KRZYMAŃSKI G., PASMYK S., DOMAŃSKI W., ROSZKIEWICZ W., BIERNACKA B. Wskazania do chirurgicznego leczenia złamań zuchwy. Czas. Stomat., 1996, 69, 11-16.
- [9] KRYST L. Chirurgia głowy i szyi. Wydawnictwo Lekarskie PZWL 1995.
- [10] KRYST L. Chirurgia szczękowo-twarzowa. Wydawnictwo Lekarskie PZWL 1993.
- [11] KRYST L., PIEKARCZYK J., MLOSEK K., WANYURA H., SZMURZYŁO W., BARAMOW P., SIEMIŃSKA-PIEKARCZYK B. Ocena odległych wyników leczenia złamań zuchwy. Czas. Stomat., 1990, 63, 85-90.
- [12] MLOSEK K. Radiologia stomatologiczna i szczękowo-twarzowa. Meddentpress, 1995.
- [13] POGORZELSKA-STRONCZAK B., CIEŚLIK T., WĄSEK A., SZPOREK B. Ocena leczenia złamań kości twarzy płytkami zespalającymi odłamy na podstawie pięcioletniego materiału klinicznego. Czas. Stomat., 1996, 69, 4, 261-268.
- [14] RIX L., STEVENSON A. R., PUNNIO-MORTHY A. Analysys of 80 cases of mandibular fractures treated with miniplate osteosynthesis. Int. J. Oral. Maxillofac. Surg., 1991, 20, 337-341.
- [15] RÓŻYŁO T. K., JARZĄB G., MAŚLANKO G. Zastosowanie minipłytek do osteosyntezy kości szczęki i zuchwy. Czas. Stomat., 1993, 66, 2-3, 183-187.
- [16] TOMASZEWSKI T., STODÓLKIEWICZ A., KOLIŃSKI P., BARTOSZCZE-TOMASZEWSKA M. Zastosowanie mini i mikroplytek w leczeniu złamań kości czaszki twarzowej. Mag. Stomat., 1997, 1, 18-21.
- [17] WHAITES E. Podstawy radiodiagnostyki stomatologicznej. Sanmedica, 1994.

